

Hydrogel-coated coils for the treatment of cerebral aneurysms: preliminary results

ADAM S. ARTHUR, M.D., M.P.H., STEPHANIE A. WILSON, R.N., SANAT DIXIT, M.D.,
AND JOHN D. BARR, M.D.

*Semmes-Murphey Neurologic and Spine Institute and Mid-South Imaging and Therapeutics;
and Baptist Memorial Hospital, Memphis, Tennessee*

Object. The authors present a retrospective analysis of their initial experience with the recently developed MicroVention HydroCoil to treat patients with cerebral aneurysms. Unlike the bare metal coils initially available for endovascular treatment of aneurysms, HydroCoils have a layer of hydrogel polymer surrounding a platinum metallic core. The hydrogel polymer expands soon after making contact with blood. The expanded hydrogel polymer provides increased volumetric filling compared with bare metal coils and offers a more biocompatible surface, as demonstrated in animal models.

Methods. Over a 17-month period, the authors used HydroCoils to treat 30 patients with 33 aneurysms. All patients had been treated at least 6 months prior to data analysis. Initial treatment results as well as records of clinical and angiographic follow up were reviewed. Six-month posttreatment angiograms were available for 25 patients.

Conclusions. The HydroCoils were implanted with few complications. On angiographic follow up, a clearly defined radiolucent separation of the coils from the parent artery was noted in many of the aneurysms treated. The authors have not previously observed angiographically demonstrated lucencies separating the coils from the parent artery. This frequent, but not consistent, appearance on follow-up angiograms obtained in this study indicates that HydroCoils support significant neointimal formation across the neck of treated aneurysms. The preliminary results indicate that HydroCoils can be used safely and effectively to treat aneurysms and that these devices may allow for improved aneurysm filling.

KEY WORDS • hydrogel • aneurysm • embolization • bioactive coil • endovascular treatment

Endovascular coil embolization of cerebral aneurysms has become equal or superior to surgical clip ligation for many of these lesions.⁵⁻⁸ Nevertheless, aneurysm growth or recanalization and delayed hemorrhage remain problematic in a relatively small fraction of aneurysms treated using this technique.¹⁴ Embolic coils made of platinum have been the mainstay of therapy since the inception of the procedure. More recently, platinum coils covered with bioactive polymers have become available. We report our initial experiences with one type of bioactive coil, the HydroCoil (MicroVention, Inc., Aliso Viejo, CA). This is a retrospective assessment of our initial experience with the use of HydroCoils to treat 33 cerebral aneurysms in 30 patients.

Unlike the bare metal coils initially available for endovascular aneurysm treatment, HydroCoils have a layer of hydrogel polymer surrounding a platinum core.

Click here to view Video Clip 1. Time-lapse film obtained over

Abbreviations used in this paper: BA = basilar artery; CA = carotid artery; MCA = middle cerebral artery; PCoA = posterior communicating artery; SAH = subarachnoid hemorrhage; VA = vertebral artery; 2D = two-dimensional; 3D = three-dimensional.

a period of 20 minutes showing the significant volume expansion of the hydrogel coating. Buffers incorporated into the hydrogel delay the onset of expansion to allow time for the coil to be positioned within the aneurysm and, if necessary, removed.

The technical characteristics of the HydroCoil have been reported previously.¹⁰ The hydrogel polymer allows delayed coil expansion and presents a more biocompatible surface than bare metal, as shown in animal models. To allow passage of the coil through the microcatheter, positioning within the aneurysm, and possible coil removal, the hydrogel polymer is combined with a proprietary buffer to delay expansion of the hydrogel until several minutes after contact with blood. The fully expanded coils increase in diameter by 69 to 107%.¹³ The working time for HydroCoil insertion ranges from 5 to 7 minutes. The time varies depending on the specific type of HydroCoil and the inner diameter of the microcatheter being used to introduce the device. If this time is exceeded, removal of the coil through the microcatheter cannot be assured. Under these circumstances, withdrawal of both the coil and the microcatheter should be performed. The limited working time for HydroCoil insertion represents a fundamental difference from other embolization coils, which may be manipulated without time constraints.

CLINICAL MATERIAL AND METHODS

Patient Population

This retrospective case series includes all patients whose cerebral aneurysms were treated with HydroCoils in the first 17 months of our experience. All treatments were performed at least 6 months before data analysis, so that angiographic follow-up data are available for the majority of these patients. Every effort was made to perform routine follow-up angiography in each of these patients. Over the initial 17-month period, we used, or attempted to use, HydroCoils to treat 30 patients with 33 aneurysms. Our patient demographics and the characteristics of the aneurysms in this series are summarized in Tables 1 and 2, respectively. The patients ranged from 32 to 62 years of age (mean 52 years), and there were 11 men and 19 women. Ten patients with 10 aneurysms were treated in the setting of acute (< 30 days) SAH. The remaining 20 patients with 23 aneurysms had unruptured lesions or a remote history of SAH.

Although most of the cases represented initial treatments, five aneurysms had been previously treated either with platinum coils (four cases), or both platinum and Matrix polymer-coated coils (Boston Scientific Corp., Fremont, CA) (one case). HydroCoils were used alone (five aneurysms), in combination with platinum coils (27 aneurysms), and in combination with both platinum and Matrix coils (one aneurysm). Neuroform intracranial stents (Boston Scientific Corp.) were also used to treat 15 aneurysms.

The sizes and types of HydroCoils used varied considerably throughout our experience. Initially, relatively few diameters and lengths of HydroCoils were available to us. Most of the devices available initially had nominal diameters of 0.018 or 0.014 in. These coils were stiffer than bare metal devices and, we believed, better suited for the treatment of larger aneurysms. Subsequent availability of less stiff coils with nominal diameters of 0.010 in facilitated the treatment of smaller aneurysms. As our experience and comfort with the new coils increased, we used them with more frequency. The numbers of coils of all types and the percentage of HydroCoils used, based on the total length of all implanted coils, are detailed in Tables 3 through 6.

RESULTS

We attempted to use HydroCoils to treat 30 patients with 33 aneurysms, and the devices were successfully implanted in 28 patients with 31 aneurysms. In patients treated with HydroCoils, complete or nearly complete aneurysm occlusion was achieved in 23 individuals with

TABLE 1
Demographic data in 30 patients with 33 aneurysms

Characteristic	Value (%)
age (yrs)	32–62
mean	52
sex	
M	11 (37)
F	19 (63)
no. w/ SAH	10 (33)

TABLE 2

Aneurysm characteristics in 30 patients
in whom 33 lesions were treated with HydroCoils*

Characteristic	Value (%)
size (largest dimension)†	3–18 mm
mean	8 mm
location	
VA	1
BA apex	8
ACoA	3
PCoA	5
other CA circulation	16
embolization	
coils used primarily	17 (47)
stent-assisted	15 (42)
balloon-assisted	4 (11)

* ACoA = anterior communicating artery.

† Measurements denote diameter of patent portion of aneurysm. Largest external size was 30 mm.

‡ The total of 36 procedures includes three patients who received retreatment.

26 aneurysms. Incomplete aneurysm occlusion was noted in five patients with five lesions. In two patients with two aneurysms treated for acute SAH, incomplete occlusion of the lesions at the time of initial treatment was intentional. Technical and clinical complications were infrequent. Among the 10 patients with 10 aneurysms treated in the setting of acute SAH, a single significant but asymptomatic complication occurred during treatment. Among the remaining 20 patients with 23 unruptured aneurysms, no significant complications occurred during treatment. One asymptomatic device-related complication occurred.

We routinely perform 6-month follow-up angiography in patients treated with coil embolization. Exceptions are made for patients with severe persistent neurological def-

TABLE 3

Group 1: initial treatment of unruptured aneurysms*

Case No.	Aneurysm Location	Largest Dimension (mm)	No. of Coils	% Length That is HydroCoil	Total Coil Inserted (cm)
1	BA apex	6.7	4	61	24.7
1†	MCA	7.7	6	70	45.9
3	PCoA	10.0	6	0	54.2
4	SHA	9.5	7	54	83.7
6	OphA	13.0	18	48	219.5
9	SHA	5.5	7	27	56.6
9†	OphA	5.7	7	19	51.4
10	MCA	13.0	6	100	60.0
11	CA terminus	6.3	4	56	26.9
13	BA apex	4.5	3	28	17.9
14	BA apex	7.5	3	50	23.9
19	OphA	7.4	4	49	44.6
23	PCoA	6.8	4	57	28.0
23†	PCoA	6.0	3	100	23.0
24	OphA	6.8	1	0	7.0
25	BA apex	10.3	5	75	80.3
26	CA terminus	8.0	4	70	53.1
30	CA fusiform	11	5	100	28
mean		8	5.4	54	52

* OphA = ophthalmic artery; SHA = superior hypophysial artery.

† Patient underwent initial treatment of a second aneurysm.

Hydrogel-coated coils for the treatment of cerebral aneurysms

TABLE 4

*Group 2: initial treatment of ruptured aneurysms with attempted complete occlusion**

Case No.	Aneurysm Location	Largest Dimension (mm)	No. of Coils	% Length That is HydroCoil	Total Coil Inserted (cm)
5	BA apex	13.5	25	12	166.2
7	ACoA	10.0	6	34	44.1
15	BA apex	13.0	3	60	50.3
21	BA apex	5.4	4	28	24.7
22	PCoA	14.0	5	53	69.2
27	VA	7.3	6	100	40.0
28	ACoA	8.4	5	56	35.9
29	CA terminus	6.6	3	57	27.9
mean		10	7.1	50	57

* ICA = internal carotid artery.

icits after SAH. Follow-up angiography performed at least 5 months posttreatment was available for 20 patients with 22 aneurysms treated with HydroCoils. Eight patients with nine aneurysms did not undergo follow-up angiography; five of these patients with six aneurysms refused such follow up. All five patients are known to be alive and without clinical evidence of posttreatment hemorrhage or ischemic complications. One patient (Case 27) with one aneurysm died of SAH. One patient (Case 25) with one aneurysm died of an unrelated cause prior to follow up. One patient (Case 29) was lost to follow up.

Follow-Up Findings and Patient Classification

The results of follow-up angiography are summarized in Tables 3 through 6. Dividing the heterogeneous patients into four categories helps to clarify the results. These categories include the following: Group 1, initial treatment of unruptured aneurysms; Group 2, initial treatment of ruptured aneurysms with attempted complete occlusion; Group 3, initial treatment of selected ruptured aneurysms with intentional subtotal occlusion; and Group 4, retreatment of recurrent or previously incompletely treated aneurysms.

Group 1: Initial Treatment of Unruptured Aneurysms.

A summary of patient data for Group 1 is presented in Table 3. We treated 14 patients with 17 unruptured lesions and one patient (Case 3) with an aneurysm that had ruptured more than 30 days before treatment. In two patients (Cases 3 and 24), each with one aneurysm, attempted HydroCoil placement was unsuccessful. Our analysis of angiographic and clinical outcome is therefore based on the other 13 patients with 16 aneurysms. In these 13 patients, complete or nearly complete occlusion was achieved for all except two aneurysms (13%, Cases 4 and 25).

TABLE 5

Group 3: initial treatment of selected ruptured aneurysms with intentional subtotal occlusion

Case No.	Aneurysm Location	Largest Dimension (mm)	No. of Coils	% Length That is HydroCoil	Total Coil Inserted (cm)
12	PCoA	8.7	4	45	55.0
16	ACoA	7.0	4	24	20.7
mean		8	4	35	38

TABLE 6

Group 4: retreatment of recurrent or previously incompletely treated aneurysms

Case No.	Aneurysm Location	Largest Dimension (mm)*	No. of Coils	% Length That is HydroCoil	Total Coil Inserted (cm)
2	PCoA	11.0	6	65	62.0
4	SHA	3.0	3	50	8
5	BA apex	5.0	3	29	24.2
8	BA apex	14.0	20	24	233.4
12	PCoA	4.0	7	100	36.0
17	CA terminus	4.0	4	38	20.9
18	ICA	7.0	4	55	57.9
20	PCoA	3.5	6	16	30.4
mean		6	6.6	47	59

* Largest dimension of residual lumen, not original aneurysm size.

No permanent treatment complications occurred, although there was one asymptomatic device-related complication. One patient (Case 6) with a paraophthalmic artery aneurysm experienced brief, transient visual blurriness and scotoma the morning after treatment. Her symptoms resolved almost immediately after anticoagulation therapy was initiated, which was continued for the next day. She had also received aspirin (325 mg) and clopidogrel (75 mg) beginning 3 days before treatment and continuing for 6 weeks thereafter. Her symptoms did not recur.

Follow-up angiography performed 6 months or more posttreatment was available for 10 of the 13 patients in whom HydroCoils were implanted. Two of these patients (Cases 1 and 9) with two treated aneurysms apiece refused follow-up angiography. Both are known to be alive and with no new neurological symptoms. One patient (Case 25) died more than 1 month posttreatment of mesenteric ischemia unrelated to her aneurysm surgery. No patient experienced SAH after treatment. Follow-up angiograms obtained 6 months after initial treatment in 10 patients with 11 aneurysms demonstrated that 10 aneurysms were either unchanged or improved. A well-defined radiolucent separation of the coils from the parent artery was noted in seven of the 11 aneurysms treated. The angiographic follow-up studies of two aneurysms in two patients (Cases 4 and 6) revealed coil compaction or aneurysm growth.

An asymptomatic, device-related complication occurred in one patient (Case 4). After detachment, the end of the coil protruded slightly from the aneurysm neck. There was a small, faintly visible radiolucency present within the parent artery adjacent to the detachment zone of the coil. When we identified it, we were concerned that this radiolucent object might represent a fragment from the coil delivery system. We elected to remove the coil by using a NeuroNet endovascular retrieval device (Guidant Corp., Indianapolis, IN). The retrieved coil was found to be damaged after extraction. The "over coil" was noted to be separated from the detachment end of the device, allowing the hydrogel to separate partially from the platinum coil core. This type of device failure was subsequently determined by the manufacturer to be related to excessive force placed on the coil during its introduction through the rotating hemostatic valve. The sheath that protects the device during its insertion into the microcatheter

has since been modified by the manufacturer to prevent such coil damage. A 2-mm neck remnant persisted after extraction of the damaged device. After the intravascular manipulation required to extract the coil, we were concerned about possible endothelial injury. Therefore, we elected to terminate the procedure rather than place a Neuroform stent or balloon to perform remodeling of the aneurysm neck. Follow-up angiography studies obtained 6 months later revealed enlargement of the aneurysm neck remnant to approximately 3 mm. The patient underwent uncomplicated retreatment of the aneurysm remnant 12 months after the initial surgery; a Neuroform stent, two platinum coils, and one HydroCoil (50% by length) were used. Nearly complete aneurysm occlusion was achieved, and follow-up angiography studies obtained 6 months after retreatment confirmed complete occlusion of the aneurysm.

In one other patient (Case 6), the aneurysm's appearance had worsened on 6-month follow-up angiography studies. This 41-year-old woman had presented with a 13-mm paraophthalmic artery aneurysm with a very broad (7.5-mm) neck. The aneurysm was treated using eight HydroCoils, nine platinum coils, and two Neuroform stents. The 6-month follow-up angiography studies revealed a slight rearrangement of the coils at the neck of the aneurysm. Nevertheless, there was no defined recurrence or growth of the lesion. We elected to follow the patient closely; subsequent 12- and 18-month posttreatment angiograms have demonstrated stable occlusion of the aneurysm with minimal further changes. The patient remains asymptomatic.

We attempted to treat two patients (Cases 3 and 24), each with one aneurysm by using HydroCoils. Both patients harbored anatomically challenging aneurysms, which resulted in tenuous microcatheter positioning. After placing a Neuroform stent in one patient (Case 3), we attempted to insert a single HydroCoil-14 fully into a PCoA aneurysm, without success. We were able to occlude the aneurysm completely by using platinum coils. After placing two Neuroform stents across the neck of a paraophthalmic artery aneurysm in the other patient (Case 24), we successfully placed a single platinum coil within the lesion. We were unable to insert fully either a HydroCoil-10 or any additional platinum coils, and the aneurysm was inadequately occluded. No complications occurred during treatment of these patients.

Group 2: Initial Treatment of Ruptured Aneurysms With Attempted Complete Occlusion. A summary of patient data for Group 2 is presented in Table 4. Complete occlusion of the lesion was attempted in eight patients with eight aneurysms treated after acute SAH. Complete or nearly complete occlusion was achieved in all cases. An asymptomatic VA dissection occurred in one patient (Case 21). No other complications occurred. One patient (Case 27) died of an SAH, and one (Case 29) was lost to follow up. None of the six remaining patients experienced a repeated hemorrhage after treatment. Follow-up angiography performed 5 or more months posttreatment was available for four of these patients. The other two refused follow-up angiography; both are known to be alive and neurologically stable. Follow-up angiograms in three patients demonstrated persistent, complete, or near complete

occlusion of the aneurysms. A well-defined radiolucent separation of the coils from the parent artery was noted in one of the four aneurysms (Case 21).

The appearance of one treated aneurysm had worsened, with coil compaction noted at the neck of the lesion. This patient (Case 5) had presented with a 13.5-mm maximum dimension, trilobed, BA apex aneurysm. During the initial treatment, two HydroCoils (12% by length) had been placed into the most distal lobe of the aneurysm, far removed from its neck. We treated this lesion again by using a Neuroform stent, one HydroCoil (29% by length), and two platinum coils. No complications were encountered during retreatment and complete aneurysm occlusion was achieved. A 6-month post-retreatment angiogram demonstrated complete aneurysm occlusion, with a radiolucent separation between the coils and the parent artery.

Group 3: Initial Treatment of Ruptured Aneurysms With Intentional Subtotal Occlusion. A summary of patient data for Group 3 is presented in Table 5. In two patients, each of whom presented with a wide-necked aneurysm and acute SAH, incomplete occlusion of the lesions was intentional. There were no complications encountered during the treatment of these patients. When we treat wide-necked aneurysms in the setting of acute SAH, we rarely use Neuroform intracranial stents because they necessitate anticoagulant and antiplatelet drug use, which in turn may complicate angioplasty for treatment of vasospasm. Hemorrhagic complications are more frequent and severe when antithrombotic drugs are administered during and after treatment. Therefore, whenever possible, balloon-assisted embolization is used to achieve occlusion of such lesions. In some cases, we opt for subtotal aneurysm occlusion in the acute phase to protect against rebleeding. In these cases subsequent Neuroform stent placement and further coil embolization are performed after the patient has recovered from acute SAH.

Follow-up angiography studies were available for both of the patients in this group. Neither patient experienced a repeated hemorrhage after treatment. Follow-up angiography performed 3 months posttreatment in the patient in Case 12 revealed enlargement of the neck remnant, from 3 to 4 mm. The patient was treated again with a Neuroform stent and HydroCoils, and attained complete aneurysm occlusion without complications. The other patient (Case 16) had suffered severe permanent deficits resulting from his SAH. At his family's request, follow-up angiography was performed 8 months after the initial treatment. Persistent and unchanged occlusion of the distal chamber of his bilobed aneurysm was confirmed. We did not recommend additional treatment.

Group 4: Retreatment of Recurrent or Previously Incompletely Treated Aneurysms. A summary of patient data for Group 4 is presented in Table 6. We treated eight patients with eight aneurysms that had been previously treated using endovascular methods. In all of these aneurysms, recurrent or residual filling was demonstrated on angiographic studies obtained after their initial treatment. Five of the eight patients were initially treated at the time of acute SAH. Group 4 includes three patients (Cases 4, 5, and 12) who were initially treated with HydroCoils. These three were included in the preceding analyses of Groups 1 through 3. The remaining five patients were initially treat-

Hydrogel-coated coils for the treatment of cerebral aneurysms

ed using platinum (four patients) or platinum and Matrix coils (one patient). Seven patients underwent repeated treatment with both HydroCoils and platinum coils; Neuroform stents were also used for the repeated treatment in four of these seven patients. In one patient retreatment was performed using HydroCoils and a Neuroform stent. Complete or nearly complete aneurysm occlusion was achieved on retreatment in seven patients (87%). No complications occurred during the treatment of these eight patients.

Six-month postretreatment angiography has been completed for six patients, in all of whom there was complete or nearly complete occlusion of the aneurysm at the time of retreatment. All of their follow-up angiograms demonstrated stable or increased occlusion. All of these patients remain clinically stable as well. Only one of them demonstrated a radiolucent separation between the coils and the parent artery.

Six-month postretreatment angiography has not been performed in two patients. One, a 59-year-old man (Case 8) with a very wide-necked 20-mm BA apex aneurysm that was incompletely occluded both at initial treatment and during retreatment of a 14-mm recurrent lumen, has refused follow-up angiography. At 14 months postretreatment, he remains clinically stable and has not suffered a repeated SAH. Follow-up angiography has been postponed pending control of severe, refractory hypertension in a 51-year-old man (Case 12) 6 months after retreatment of a previously ruptured PCoA aneurysm. This patient remains neurologically intact.

ILLUSTRATIVE CASES

Figures are presented for the following two illustrative cases.

Case 26 (Group 1)

This 49-year-old woman was referred for treatment of an incidental 11-mm left CA terminus aneurysm. Admission 2D and 3D angiograms revealed a relatively narrow neck for the aneurysm.

Click here to view Video Clip 2. A 2D angiographic left CA image obtained in this patient. **Video Clip 3:** The same aneurysm in 3D rotational reconstruction.

The patient opted for endovascular treatment, and the aneurysm was occluded with four coils. An 8-mm-diameter spherical coil (Micrus Corp., Sunnyvale, CA) was placed first. Three HydroCoils (total length 37 cm) were then used to fill the aneurysm. An immediate postembolization angiogram showed complete filling of the lesion.

Click here to view Video Clip 4: An immediate postembolization angiographic image.

Subtracted (Fig. 1 *left*) and unsubtracted images (Fig. 1 *right*) from a 6-month follow-up angiogram demonstrate development of a radiolucent separation of the coils from the CA terminus. Slight interval narrowing of the proximal anterior cerebral artery had developed as well. The appearance of the lesion indicates that significant neointimal proliferation has occurred across the neck of the aneurysm.

Case 10 (Group 1)

This 41-year-old woman was discovered to have a 30-mm partially thrombosed right MCA aneurysm on computerized tomography scans (Fig. 2 *left*) obtained after she suffered a generalized seizure. The aneurysm wall was partially calcified. Pretreatment 2D angiography demonstrated a 5-mm-wide aneurysm neck involving both of the M_2 branches (Fig. 2 *right*). A pretreatment 3D arteriogram revealed that the lumen of the aneurysm measured 13 mm in maximum dimension.

Click here to view Video Clip 5. Case 10. A rotational 3D angiographic image of this patient's aneurysm.

The apparent distal M_1 stenosis seen only on the 3D angiogram is an imaging artifact. This aneurysm was thought to be a poor candidate for endovascular treatment based on multiple factors: 1) partially thrombosed aneurysms have a high rate of recurrence because the coils are usually driven into the thrombus by the blood flow; 2) even when not partially thrombosed, wide-necked aneurysms arising at arterial bifurcations have high rates of recurrence after coil occlusion; and 3) achieving complete occlusion of the aneurysm with preservation of both M_2 branches was predicted to be very difficult. Two experienced cerebrovascular neurosurgeons believed that open surgical treatment would also be difficult. Two key points emerged from our discussion of treatment options and techniques. First, if endovascular treatment failed because the coils were driven into the thrombosed portion of the aneurysm, the vascular neurosurgeons did not believe that their surgical approach would be altered; and second, if direct clip placement proved to be impossible, a bypass to only one of the two M_2 branches would likely be feasible. Both neurosurgeons requested that we attempt to use coils to occlude the aneurysm.

We attempted to place a Neuroform stent from the proximal MCA into the inferior division M_2 branch. The tip of the stent delivery catheter would not pass beyond the calcified neck of the aneurysm. With assistance from a 7×7 -mm Hyperform balloon (Micro Therapeutics, Inc., Irvine CA), we placed six HydroCoils (60 cm total length) into the aneurysm (Fig. 3 *left*). A small neck remnant remained. After removal of the balloon, part of the last coil that was placed prolapsed into the MCA bifurcation (Fig. 3 *right*). The patient was maintained on full anticoagulation therapy overnight. Aspirin and clopidogrel were continued, and the patient remained asymptomatic. At the 6-week follow-up visit, angiography revealed a smaller neck remnant and indicated partial neointimal coverage of the neck (Fig. 4 *upper*). Subtracted (Fig. 4 *center*) and unsubtracted (Fig. 4 *lower*) images from 6-month follow-up angiography demonstrate complete occlusion of the aneurysm, with radiolucent separation of the coil mass from the arterial bifurcation. The patient remained asymptomatic at the 12-month clinical follow-up visit.

DISCUSSION

Although endovascular coil embolization of appropriately selected cerebral aneurysms has been well proven to be equivalent or even superior to traditional clip ligation, incomplete aneurysm occlusion remains problematic in

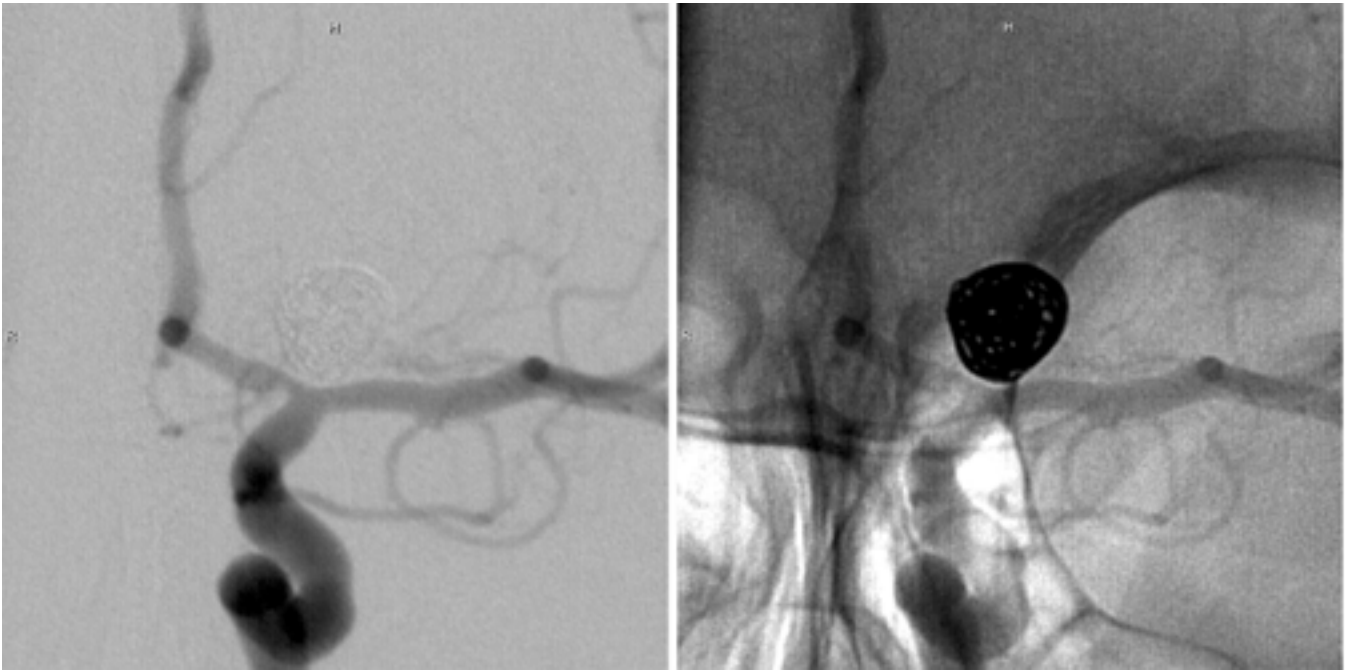

Fig. 1. Case 26. Subtracted (*left*) and unsubtracted (*right*) 6-month follow-up angiographic studies revealing development of a radiolucent separation of the coils from the CA terminus.

some cases.⁵⁻⁸ Delayed rupture or continued growth may occur when an aneurysm has not been completely excluded from the circulation. Embolization of lesions with bare metal coils carries a small but well-recognized risk of failure due to inadequate aneurysm occlusion.⁵ Shortly after the inception of endovascular coil embolization, the necessity of filling the aneurysm as completely as possible,

particularly the neck of the lesion, was shown to be critical to achieve a durable treatment.^{3,4} Large aneurysms and those with large necks were quickly discovered to have higher rates of treatment failure.¹¹

Platinum coils induce and support a relatively minimal biological tissue growth response, so that the desired formation of a complete neointimal covering across the neck

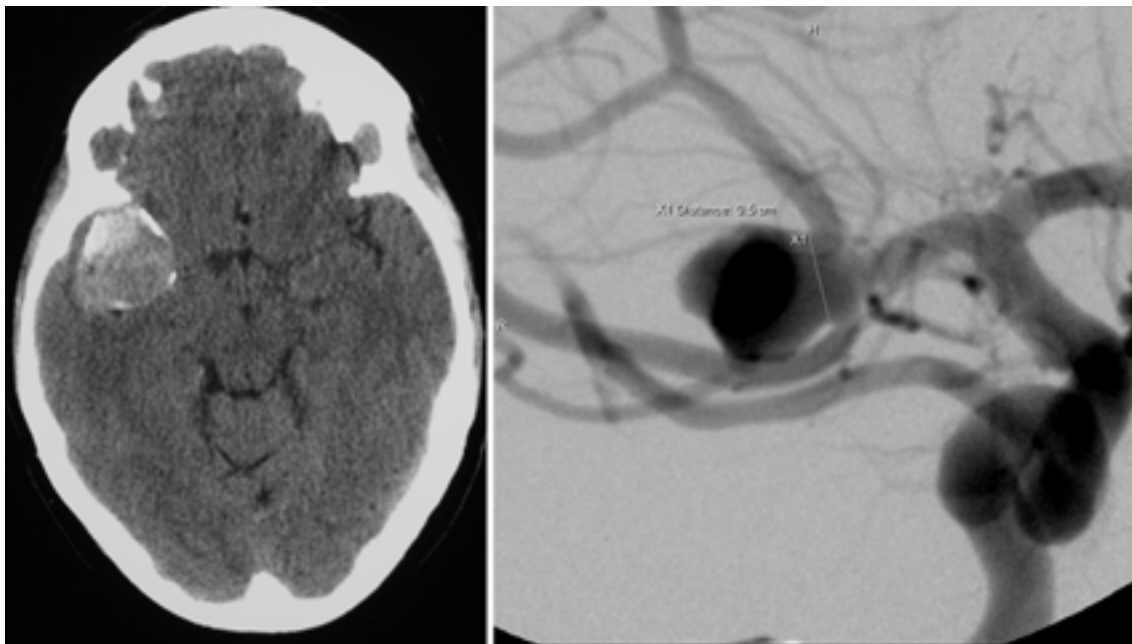


Fig. 2. Case 10. *Left*: Pretreatment computerized tomography scan obtained for workup of a generalized seizure reveals a 30-mm, partially thrombosed right-sided MCA aneurysm. *Right*: A 2D angiographic image demonstrating a right-sided MCA aneurysm with a 5-mm neck involving both M₂ branches.

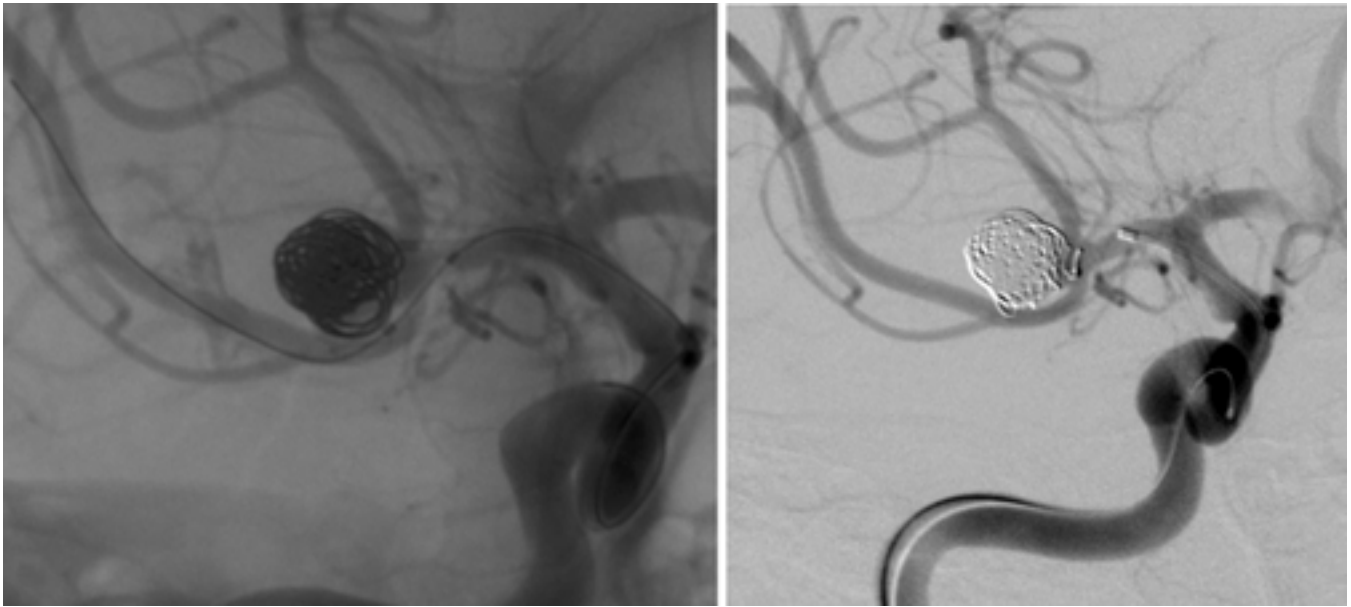


Fig. 3. Case 10. Angiographic images obtained during treatment of this patient. *Left:* The partially treated aneurysm with small remaining neck remnant is demonstrated. *Right:* Coil prolapse into the MCA bifurcation after balloon removal is revealed.

of a treated aneurysm does not occur in many cases.¹ HydroCoils were designed to improve on the two key weaknesses of endovascular aneurysm therapy. The delayed expansion of the hydrogel allows for significantly better volumetric filling of the aneurysm.^{2,9,15} In animal models, HydroCoils have also been shown to present a more biocompatible surface than platinum, with significantly increased neointimal coverage of the neck of the aneurysm and infiltration of the coil mass with mature vascularized fibrous tissue.⁹ Although their efficacy is well supported by laboratory research, clinical data regarding HydroCoil use in humans remain limited.

In our initial experience with HydroCoils, we discovered several fundamental technical differences between these devices and bare metal coils. Perhaps most importantly, because of their delayed expansion characteristics, HydroCoils must be delivered within a relatively short period of time. This period ranges from approximately 5 to 7 minutes, depending on the types of HydroCoil and microcatheter. If this time limit is exceeded, the coil may increase in diameter so that it can no longer be removed through the microcatheter. In that event, the HydroCoil may still be removed as long as the microcatheter is extracted along with it. Catheter access to the aneurysm is of course lost in this event. In our experience, the working time limits recommended by the manufacturer are realistic and should not be assumed to be conservative.

Preparation of HydroCoils for use is slightly more complex than that of bare metal coils. The HydroCoils should be hydrated until they assume a tightly coiled configuration. Hydration in room-temperature normal saline is a lengthy process. For this reason, hydration using warm saline or brief exposure to steam is recommended. Coil stiffness is markedly reduced when the devices are well hydrated before use.

Even when well hydrated, HydroCoils are stiffer than many bare metal coils. This stiffness, in combination with a finite working time, mandates solid microcatheter purchase within the aneurysm. As the HydroCoil is exposed to blood, its stiffness rapidly decreases. This decreasing stiffness is apparent both by visual and by tactile feedback. Although it seems counterintuitive given the limited working time, slow insertion of the coil and occasional pauses during coil advancement helps to maintain catheter position within the aneurysm.

Over the first 2 years of our experience with HydroCoils, we have seen few device- or treatment-related complications. To date, we have used these devices in more than 75 cases. The HydroCoil's relatively increased stiffness compared with platinum coils has not resulted in an increased incidence of complications.

As with any new endovascular device, we were concerned that thromboembolic complications might be increased with HydroCoils, but we did not find this to be true. As described earlier, one of our patients (Case 6) experienced brief, transient visual symptoms believed to represent an embolic phenomenon. No other thromboembolic complications were observed. According to the manufacturer, HydroCoils have the same thrombogenicity as normal saline and bare platinum. Nevertheless, in a recent report increased thrombus formation with the use of HydroCoils has been documented in a canine model.¹⁵ We should note that all of our electively treated patients received dual antiplatelet medication (aspirin and clopidogrel) before and after embolization.

In a recent report, researchers have questioned whether aneurysm embolization with a combination of HydroCoils and Matrix coils might be responsible for chemical meningitis in two patients.¹² We have not observed this phenomenon to date, although we have used this combination

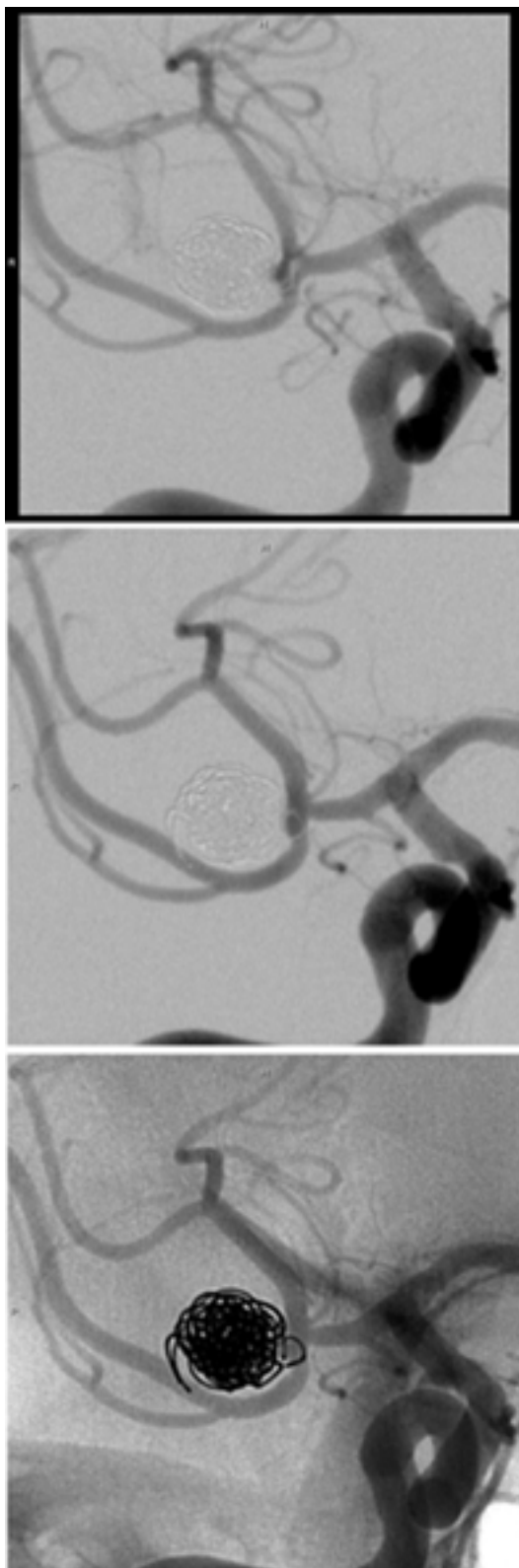


Fig. 4. Case 10. Angiographic images demonstrating follow-up findings in this patient. *Upper*: Initial neointimal coverage of the aneurysm neck at 6 weeks. *Center and Lower*: Subtracted (*center*) and unsubtracted (*lower*) views obtained at the 6-month follow-up review demonstrating a radiolucent separation of the coil mass from the arterial bifurcation.

of coils to treat only one patient (Case 8). In that case, implantation of the Matrix coils preceded implantation of the HydroCoils by several weeks.

In our case series, follow-up angiography demonstrated development of a radiolucent separation between the coils and the parent artery in nine aneurysms. Several aneurysms treated with multiple platinum “framing” coils placed across the neck of the lesion later displayed this radiographic finding. Subsequently placed HydroCoils were deposited more centrally within the aneurysms. In addition, this characteristic finding was not seen on immediate posttreatment angiograms, even when the aneurysm was treated with HydroCoils alone. Therefore, we believe this observation is not simply a result of hydrogel expansion at the neck of the aneurysm. The radiolucent separation of the coils from the parent artery appears to represent neointimal tissue covering the coils at the neck of the aneurysm.

We have not previously observed such radiolucent separation of bare platinum coils from the artery. Nor, to our knowledge, has this been reported by others. Although pathological data remain unavailable for patients treated with HydroCoils, this characteristic radiographic finding indicates that significantly improved neointimal coverage of the aneurysm neck does occur in humans. Twenty aneurysms treated with HydroCoils, in which 6-month follow-up angiographic studies were available, were judged to be completely or nearly completely occluded. Only two (10%) of these aneurysms (Cases 5 and 6) had a worse angiographic appearance at the time of follow-up review. This relatively low recurrence rate supports the clinical effectiveness of the HydroCoils.

CONCLUSIONS

Our limited and preliminary experience supports the claim that HydroCoils are safe and effective for the endovascular treatment of cerebral aneurysms. Treatment complications were infrequent and were not increased relative to our experience with bare metal coils. Device-related complications were rare, and delayed aneurysm growth or recanalization was infrequent. The development of a radiolucent separation between the coils and the parent artery on follow-up arteriograms in some patients indicates that improved neointimal coverage of the aneurysm neck does occur in humans. The physical characteristics of the coils demand certain changes in the insertion technique, primarily related to the finite time allowed for coil delivery. Nevertheless, the potential for more complete and durable aneurysm occlusion by using HydroCoils far outweighs the relatively minor technical considerations related to their use.

Disclosure

Dr. Barr is a paid consultant of MicroVention, Inc.

References

1. Bavinzski G, Talazoglu V, Killer M, et al: Gross and microscopic histopathological findings in aneurysms of the human brain treated with Guglielmi detachable coils. *J Neurosurg* **91**: 284–293, 1999
2. Cloft HJ, Kallmes DF: Aneurysm packing with HydroCoil Em-

Hydrogel-coated coils for the treatment of cerebral aneurysms

- bolic System versus platinum coils: initial clinical experience. **AJNR** **25**:60–62, 2004
3. Guglielmi G, Viñuela F, Dion J, et al: Electrothrombosis of saccular aneurysms via endovascular approach. Part 2: Preliminary clinical experience. **J Neurosurg** **75**:8–14, 1991
 4. Guglielmi G, Viñuela F, Sepetka I, et al: Electrothrombosis of saccular aneurysms via endovascular approach. Part 1: Electrochemical basis, technique, and experimental results. **J Neurosurg** **75**:1–7, 1991
 5. International Subarachnoid Aneurysm Trial (ISAT) Collaborative Group: International Subarachnoid Aneurysm Trial (ISAT) of neurosurgical clipping versus endovascular coiling in 2143 patients with ruptured intracranial aneurysms: a randomised trial. **Lancet** **360**:1267–1274, 2002
 6. Johnston SC: Effect of endovascular services and hospital volume on cerebral aneurysm treatment outcomes. **Stroke** **31**:111–117, 2000
 7. Johnston SC, Dudley RA, Gress DR, et al: Surgical and endovascular treatment of unruptured cerebral aneurysms at university hospitals. **Neurology** **52**:1799–1805, 1999
 8. Johnston SC, Wilson CB, Halbach VV, et al: Endovascular and surgical treatment of unruptured cerebral aneurysms: comparison of risks. **Ann Neurol** **48**:11–19, 2000
 9. Kallmes DF, Cloft HJ: The use of hydrocoil for parent artery occlusion. **AJNR** **25**:1409–1410, 2004
 10. Kallmes DF, Fujiwara NH: New expandable hydrogel-platinum coil hybrid device for aneurysm embolization. **AJNR** **23**:1580–1588, 2002
 11. Malisch TW, Guglielmi G, Viñuela F, et al: Intracranial aneurysms treated with the Guglielmi detachable coil: midterm clinical results in a consecutive series of 100 patients. **J Neurosurg** **87**:176–183, 1997
 12. Meyers PM, Levine SD, Fitzsimmons BF, et al: Chemical meningitis after cerebral aneurysm treatment using two second generation aneurysm coils: report of two cases. **Neurosurgery** **55**:1222, 2004
 13. Microvention, Inc: **HydroCoil Package Insert**. Aliso Viejo, CA: Microvention, 2004
 14. Murayama Y, Nien YL, Duckwiler G, et al: Guglielmi detachable coil embolization of cerebral aneurysms: 11 years' experience. **J Neurosurg** **98**:959–966, 2003
 15. Yoshino Y, Niimi Y, Song JK, et al: Endovascular treatment of intracranial aneurysms: comparative evaluation in a terminal bifurcation aneurysm model in dogs. **J Neurosurg** **101**:996–1003, 2004

Manuscript received December 22, 2004.

Accepted in final form January 7, 2005.

Address reprint requests to: John D. Barr, M.D., MidSouth Imaging and Therapeutics, 6305 Humphreys Boulevard, Suite 205, Memphis, Tennessee 38120.